



## Prenatal visualization of the fetal uterus in routine 2D ultrasound examination

Pedro Azumendi, Marisa Borenstein, Jesús Salvador Jiménez, Ernesto González-Mesa, Carlos Corrales, Guillermo Azumendi, Ignacio Alonso-Usabiaga, Juan Gómez-Salgado & Francisco Javier Fernández-Carrasco

To cite this article: Pedro Azumendi, Marisa Borenstein, Jesús Salvador Jiménez, Ernesto González-Mesa, Carlos Corrales, Guillermo Azumendi, Ignacio Alonso-Usabiaga, Juan Gómez-Salgado & Francisco Javier Fernández-Carrasco (2025) Prenatal visualization of the fetal uterus in routine 2D ultrasound examination, *Annals of Medicine*, 57:1, 2449226, DOI: [10.1080/07853890.2024.2449226](https://doi.org/10.1080/07853890.2024.2449226)

To link to this article: <https://doi.org/10.1080/07853890.2024.2449226>



© 2025 The Author(s). Published by Informa UK Limited, trading as Taylor & Francis Group



Published online: 09 Jan 2025.



Submit your article to this journal [↗](#)










View related articles [↗](#)



View Crossmark data [↗](#)

## Prenatal visualization of the fetal uterus in routine 2D ultrasound examination

Pedro Azumendi<sup>a,b</sup> , Marisa Borenstein<sup>a</sup> , Jesús Salvador Jiménez<sup>b</sup> , Ernesto González-Mesa<sup>b</sup>, Carlos Corrales<sup>a,b</sup> , Guillermo Azumendi<sup>a</sup>, Ignacio Alonso-Usabiaga<sup>a</sup> , Juan Gómez-Salgado<sup>c,d</sup>  and Francisco Javier Fernández-Carrasco<sup>e</sup> 

<sup>a</sup>Fetal Medicine and Prenatal Diagnosis Unit, Centro Gutenberg, Málaga, Spain; <sup>b</sup>Research Group in Maternofoetal Medicine, Epigenetics, Women's Health, and Reproductive Health, Department of Obstetrics and Gynaecology, Hospital Regional Universitario, Málaga, Spain; <sup>c</sup>Department of Sociology, Social Work and Public Health, Faculty of Labour Sciences, University of Huelva, Huelva, Spain; <sup>d</sup>Safety and Health Postgraduate Programme, Universidad Espiritu Santo, Guayaquil, Ecuador; <sup>e</sup>Department of Nursing, Faculty of Health Sciences of Ceuta, University of Granada, Ceuta, Spain

### ABSTRACT

**Objective:** To establish a new technique to easily identify the fetal cervix-uterus complex in normal female fetuses from 20 to 40 weeks of gestation.

**Material and methods:** The study was performed in routine examination in normal fetuses by two observers. Twenty-five consecutive cases per gestational week were assessed between 20 and 40 weeks. The same plane of the bladder used in the assessment of the umbilical arteries was used. In this transverse view of the fetal pelvis different structures can be identified from front to back: the bladder, the bowel and the vertebral body. If the uterus is present, it can be seen between the bladder and the rectum, as a round structure pushing the posterior bladder wall. The echogenicity changes as the uterus develops and increases its size. Voluson E10 ultrasound device (GEHealthcare Ultrasound®, Zipf, Austria) equipped with an RM6Cprobe was utilized.

**Results:** Successful identification of the cervix-uterus complex was possible overall in 83.4% of cases, reaching more than 93% from 31 weeks onwards. There was a rapid growth of the cervix-uterus complex after 26 weeks, and in the third trimester appears as a solid round structure behind the fetal bladder. Reproducibility analysis showed agreement between 2 observers in 92% of cases.

**Conclusion:** Identification of the uterus and cervix complex is possible from 20 weeks, although it is easier at the end of gestation. This reproducible technique allows the anatomical study of normal female fetuses and the visualization of kidney malformations and disorders of sexual development.

### KEY MESSAGES

- Identification of the uterus and cervix complex is possible from 20 weeks, although it is easier at the end of gestation.
- The assessment of the uterus and cervix complex could be a useful evaluation in the anatomical study of normal female fetuses, and of critical importance in those fetuses with kidney malformations or disorders of sexual development.

### ARTICLE HISTORY

Received 7 February 2024

Revised 25 May 2024

Accepted 25 August 2024

### KEYWORDS

Fetal uterus; internal genitalia; prenatal ultrasound; disorders of sex differentiation

## Introduction

Development of genital organs begins as early as 6 weeks of gestation in the fetus, when germinal cells migrate from the extraembryonic endoderm in the yolk sac towards its definitive location in the developing gonad [1]. Urinary and genital systems have a common pathway and some of the structures appear simultaneously in the embryo. This process is

influenced by many genetic and hormonal factors that facilitate its normal development and the adequate differentiation of internal and external genitalia in the male and female fetus. This is a complex process in which the balance between induction and inhibition of certain pathways with a specific timing is critically important for the development of normal structures [1].

**CONTACT** Juan Gómez-Salgado  [jgsalgad@gmail.com](mailto:jgsalgad@gmail.com), [salgado@uhu.es](mailto:salgado@uhu.es)  Department of Sociology, Social Work and Public Health, Faculty of Labour Sciences, University of Huelva, Avda. Tres de Marzo, S/N, 21007 Huelva, Spain

© 2025 The Author(s). Published by Informa UK Limited, trading as Taylor & Francis Group

This is an Open Access article distributed under the terms of the Creative Commons Attribution-NonCommercial License (<http://creativecommons.org/licenses/by-nc/4.0/>), which permits unrestricted non-commercial use, distribution, and reproduction in any medium, provided the original work is properly cited. The terms on which this article has been published allow the posting of the Accepted Manuscript in a repository by the author(s) or with their consent.

There are several conditions that may interfere with these steps and generate renal defects, genital malformations or both. Postnatal evaluation of external genitalia is easy for paediatricians as well as internal organs are for sonographers and radiologists [1]. However, in prenatal diagnosis, images are not always as clear and certain internal structures are not feasible to image accurately. Sulac et al. [2] reported in an anatomopathological study in 80 aborted fetuses between 10-40 weeks of gestation the different shapes of the fetal uterus and the different growth of the cervix and fundus. They described that the cervix is wider compared to the fundus of the uterus in second trimester and of similar width at term. They have also shown that the uterus is in the middle of the pelvis overall in 57% of all cases, but in the third trimester is more likely to be deviated to the left or to the right. However, the correct identification of the uterus in prenatal life has only been described in a few studies published more than ten years ago [3, 4]. Soriano et al. [3] published in 1999 that there is a linear growth of the uterus width and circumference in 140 normal cases between 19 and 38 weeks of gestation. However, they could only assess the uterus in 77,8% of female fetuses and reported good interobserver reproducibility. Other publications only refer to the space between the bladder and the rectum (anogenital distance) being larger in female compared to male fetuses but did not describe the sonographic appearance or development of fetal cervix and uterus [5, 6].

The aim of this study was firstly, to establish the technique to easily identify the fetal cervix-uterus complex (CUC) in normal female fetuses in second and third trimester of pregnancy with routine two-dimensional (2D) ultrasound (US) employing the latest US technology; secondly to understand the modification in the ultrasound appearance of the cervix-uterus complex as gestation advances and thirdly to explore the reproducibility of the proposed technique.

## Material and methods

This was a cross-sectional descriptive study in singleton pregnancies with normal grown female fetuses. We selected 25 consecutive cases per gestational week which were assessed between 20 and 40 weeks. They attended our Center for routine assessment between January 2021 and September 2021. Pregnancies were dated by certain LMP or first trimester US. We only included fetuses with no obvious defect and those that were not considered to be at high risk of internal or external genital abnormalities, according to maternal and previous pregnancies history. Fetuses

examined prior to 24 weeks of gestation were re-scanned in the third trimester at 30 weeks to confirm the previous findings, but were only included once in the present study. Demographic data were collected from the mother before the scan and all patients agreed to sign the informed consent. The allocated time for the whole examination was 25 min. All scans were done by transabdominal US using a Voluson E10 ultrasound machine (GE Healthcare Ultrasound®, Zipf, Austria) equipped with an RM6C probe. The study adhered to the ethical guidelines outlined in the Declaration of Helsinki and was approved by the Malaga Provincial Research Ethics Committee, belonging to the government of the region of Andalusia, Spain (code 0102-N-24) and all participants gave their written informed consent to participate in this study.

Transvaginal (TV) scan improves the identification of the structures when the fetus lies in breech presentation, since the borders of the bladder and the rectum appear more defined. This approach is not mandatory, but as in any other fetal assessment, TV scan increases the success rate in difficult cases with poor US transmission and in particular for the CUC identification when assessing before 24 weeks of gestation.

A series of simple steps were followed with the intention to identify the fetal CUC in a transverse view between the bladder and the rectum. This technique was adopted by the research team in the process of understanding the development of the fetal uterus, as previous publications did not mention the exact plane for assessing the uterus, nor did they distinguish between the other pelvic organs of the fetus, such as vagina or cervix, and the fundus of the uterus. With this proposed method of assessment, the team managed to show the different appearance of the fetal CUC along gestation. Other publications have provided measurements [3], but here the changes in the appearance of the CUC were demonstrated with higher resolution of the images obtained. This three-step technique can also help to standardize the assessment and understanding of CUC modifications throughout gestation.

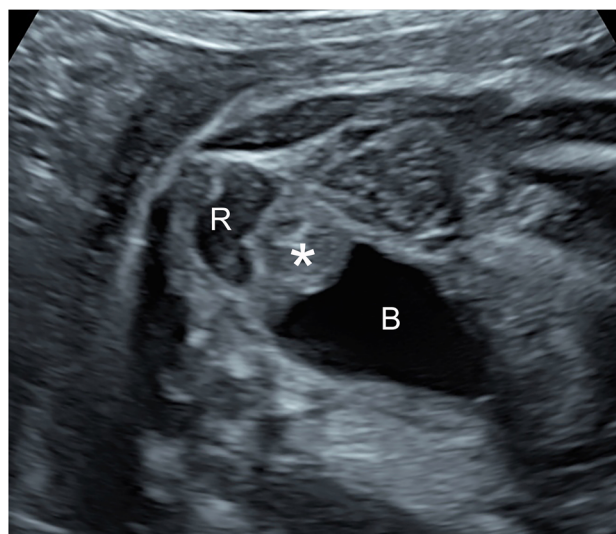
The steps are described as follows (Figure 1):

1. Locate the fetal bladder in a transverse view at the level used to assess the presence of the umbilical arteries surrounding the bladder. It is recommended to enlarge the image to focus solely on the pelvic organs, as seen in Figure 1. The structures shall be located in the center of the image and the contrast shall be increased

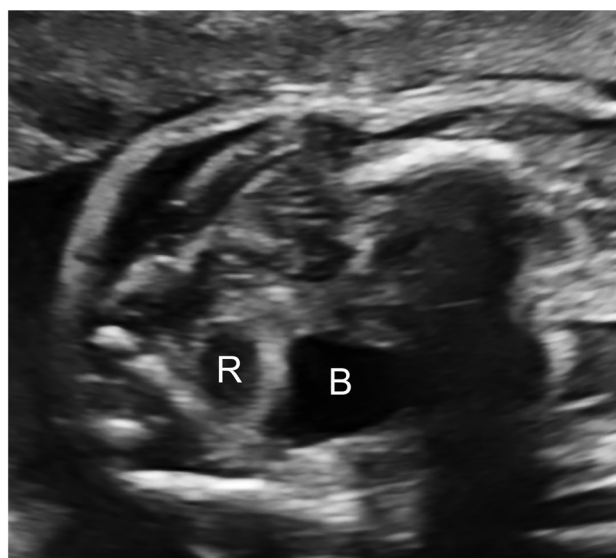by changing the gain parameters according to US transmission and gestational age in each case; speckle reduction imaging (SRI) was used as in most standard settings, with values between 2 and 4.

2. Identify a vertebral body posteriorly, the rectum in front of the spine and the bladder anteriorly. The rectum is seen as a round structure with echogenic borders that may show anechoic or hypoechoic filling depending on the gestational age. As gestation advances, the bowel is larger and less echogenic, enhancing the contrast with surrounding structures. A full or half full bladder helps in the adequate identification of fetal pelvic structures. In early gestation, waiting until a full bladder is seen is highly recommended in order to improve the differentiation of structures, however in third trimester, even with an empty bladder, the uterus and rectum could be imaged with a clear definition of their limits.
3. If the uterus is present, another round structure is identified between the bladder anteriorly and the bowel posteriorly. At this level two lines will be seen: the posterior bladder wall and the anterior limits of the CUC. Behind the uterus lies the rectum. At early gestations, the uterus may look hypoechoic (like fluid-filled) but as gestation advances it becomes more echogenic giving the typical solid appearance on US. The bowel's development shows the opposite trend, from echogenic to anechoic, this facilitates the distinction between them. A half-full or full bladder increases the chances of the uterus visualization. The CUC generates a protrusion or convex image into the posterior bladder wall. When the uterus is absent, the bowel and the bladder can be identified very closed to each other with no free space or other structures interposed between them. Bladder and bowel are then wall to wall (Figures 1 and 2).

In order to assess interobserver variability, two observers were given 50 stored US images of fetal transverse view of the bladder, randomly chosen by one of the authors who did not participate in the reproducibility assessment and who was aware of the fetal gender assigned by US in the routine examination performed. The images belonged to female and male fetuses from 20 to 40 weeks of gestation and the operators had to mention whether the uterus was present or absent. The observers were blind to the



**Figure 1.** 2D Ultrasound image in a female fetus at 28 weeks of gestation showing the presence of the fetal uterus. The bladder can be identified in front of it, full of urine which increases the visualization of the limits of each structure, and the rectum behind the uterus. Note that the uterus has a solid appearance, while the bowel is already showing fluid content. The uterus is “pushing” the posterior bladder wall giving the convex appearance (R: rectum; B: bladder; \*: uterus or cervix-uterus complex).



**Figure 2.** 2D Ultrasound image in a male fetus at 28 weeks of gestation showing the bladder and its relationship with the bowel behind it. Note that there is no space between them, and the posterior wall of the bladder is in contact with the anterior wall of the rectum. The content of the structure between the spine and the bladder has anechoic content, typically seen in the bowel at this stage of pregnancy (R: rectum; B: bladder).

fetal gender and external genitalia were not present in the given pictures.

In a subgroup of fetuses who showed the spine closer to the probe (spine anterior) from 30 weeks

onwards, a sagittal view of the CUC was attempted. When the bladder is full, the vagina and the distal part of the CUC can be identified lying between the bladder anteriorly and the bowel posteriorly (Figure 3). In late gestation, the rectum has usually some content that helps the identification of borders and delimitation of all different fetal pelvis organs. With this approach the fundal part of the uterus looks thinner than the cervix and it is usually not located in the midline but pushed laterally by the adjacent structures. Therefore, in sagittal views the CUC must be looked by slightly moving the transducer away from the midline, to right or left. When it is possible to obtain this view, the vagina can also be imaged, showing an echogenic line in the center. The CUC may also display a central line that could appear anechoic in early gestations or echogenic later, near term, and it is likely to be caused by the normal secretion of the cervical and endometrial cells induced by higher hormonal levels.

## Results

We selected 25 consecutive singleton pregnancies between 20 and 40 weeks of gestation with female fetuses to assess. We obtain 525 cases between January 2021 and September 2021.

Identification of CUC was possible in 438 out of the 525 examined cases (83.4%).

We failed to identify the CUC in 87 cases (16.6%) and the reasons were:

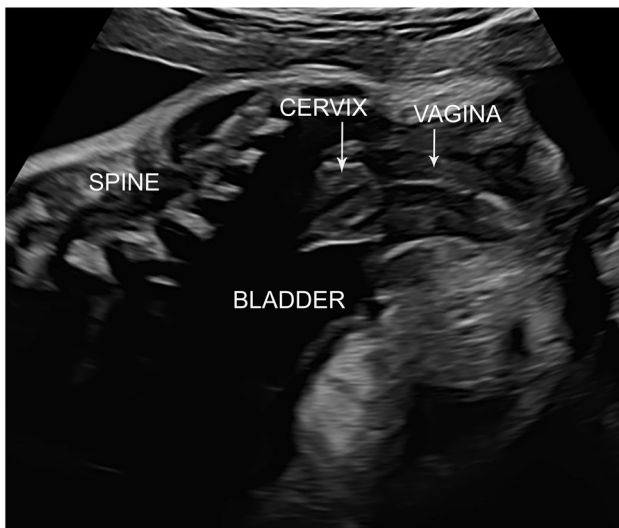
- Early gestation before 24 weeks in 50 cases (9.5% of the total).
- Fetal position or interposed fetal structures 27 (5.1% of the total).
- Increased maternal BMI with fetus in cephalic presentation 10 (2%).

In the 438 fetuses in which the CUC could be seen, the median gestational age (GA) was 32 weeks (range 20–40), and the median maternal BMI was 23 (range 17–37). In Table 1 the results of the CUC visualization according to gestational age groups are summarized.

In Figure 4 we show the development of CUC and sonographic changes along gestation. The pelvic structures used as landmarks undergo physiological modifications, as well as the CUC. These physiological modifications should be understood to improve the identification and reduce mistakes in the CUC assessment.

Reproducibility analysis was performed by two of the authors using stored images of the cross-sectional view of the fetal pelvis at the bladder level. They agreed in the correct identification of the presence or absence of the fetal uterus in 92% of the cases. Failures were seen at early gestation fetuses before 24 weeks or in cases with prominent bowel behind the bladder that was mistaken with CUC in male fetuses. In all of the 8% of cases in which no agreement between the operators was achieved, in early gestation, the male fetus showed a small bowel that was mistaken with the fetal uterus and, in late gestation, there was one case of a female fetus where the uterus was mistaken with the rectum, and the uterus was considered absent. These results are shown in Table 2.

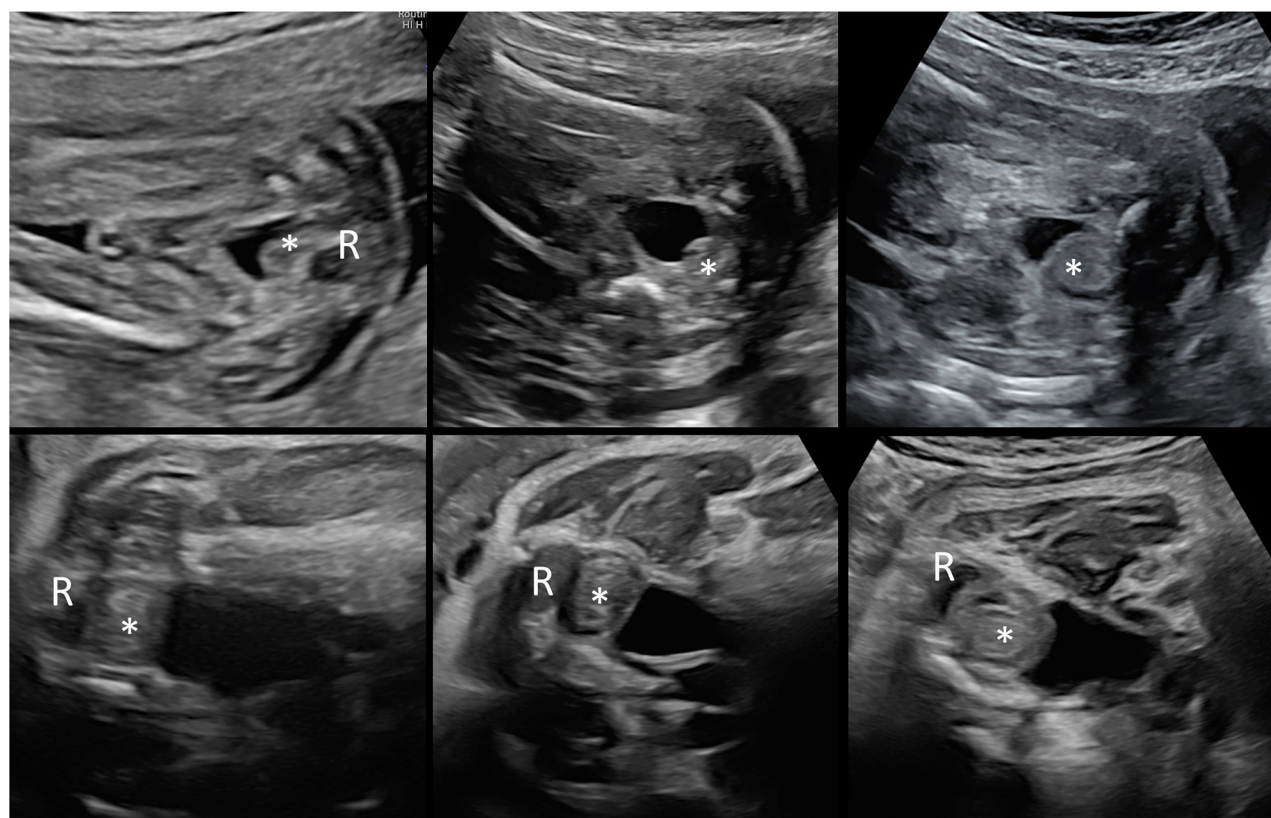
In the subgroup of fetuses above 30 weeks included for the sagittal view assessment of pelvic organs, we could include 50 cases, since only fetuses showing the spine anteriorly were included (25% of fetuses above 30 weeks of gestation) (Figure 3). We were able to visualize the vagina and CUC in 80% of the cases. We confirm that a full bladder and the occupied rectum enhances the contrast between adjacent structures and helps in the correct identification. All these cases were examined transabdominally.



**Figure 3.** 2D Ultrasound image of the cervix-uterus complex in a sagittal view in a normal female fetus at 34 weeks of gestation. The spine is anterior, the bowel can be seen close to the spine and the uterus anteriorly between the rectum and the bladder.

**Table 1.** Fetal cervix-uterus complex visualization between 20 and 40 weeks.

Gestational age (weeks)	Total cases	Fetal cervix-uterus complex identification (n and %)
20–24	125	75 (60%)
25–30	150	128 (85.3%)
31–36	150	140 (93.3%)
37–40	100	95 (95%)
Total cases	525	438 (83.4%)



**Figure 4.** 2D Ultrasound images of normal female fetuses at 20, 24, 28, 32, 36 and 40 weeks of gestation. Note the change in appearance from a small hypoechoic structure behind the bladder at 20 weeks to a big round solid and heterogeneous uterus by 40 weeks. From 26 to 28 weeks it appears homogeneous and as gestation progresses the hormonal effect makes it look different. It is clearly distinguished from the bowel that lies behind in late gestation. (R: Rectum; \*: uterus or cervix-uterus complex).

Following the data collection of images from 20 to 40 weeks of gestation, we have noticed how the CUC changes along gestation (Figure 4). The appearance of the bladder remains similar as a round anechoic structure, which is located anteriorly in the pelvis, that may only modify its size according to fetal micturition. However, both the CUC and the bowel show differences along the study period. From the 20th to 24th week of gestation the CUC is small, round and shows an echogenic appearance; the bowel, on the contrary, appears echogenic with a more solid appearance since it is still not functional. While gestation advances and the level of certain hormones increases, from the 26th week of gestation the CUC grows rapidly and becomes echogenic, so it can be identified as a solid round structure behind the posterior bladder wall. At the same time, the bowel begins to show a rapid development and its peristaltic movements allow the fluids to move inside. Therefore, the bowel, located at the posterior pelvic space, becomes anechoic. These findings in the late second and third trimester allow and facilitate the adequate differentiation of the three main fetal structures in the pelvic space: anechoic bladder anteriorly, echogenic CUC in the middle and anechoic rectum posteriorly.

**Table 2.** Results on agreement between 2 operators in the assessment of the presence of uterus in 50 cases including female and male fetuses between 20 and 40 weeks of gestation.

Gestational age (weeks)	Total cases	Female fetus	Male fetus	Agreement between operators 1 and 2 (cases and %)	Gender in failure cases
20–24	10	5	5	9 (90%)	f:0; m:1
25–30	10	5	5	9 (90%)	f:0; m:1
31–36	16	8	8	15 (93.5%)	f:0; m:1
37–40	14	7	7	13 (92.8%)	f:1; m:0
Total	50	25	25	46 (92%)	f:1; m:4

Abbreviations: f: female; m: male.

These physiological modifications in the US characteristics of CUC may explain why it is more complicated to identify the fetal uterus at the 20<sup>th</sup> week as compared to the third trimester.

## Discussion

In this study, we proposed a simple assessment of the fetal CUC, in only three steps. Employing this method, we achieved a high success rate in the global visualization of the CUC (83.4% between 20 and 40 weeks of gestation) but this numbers are even higher in the group of fetuses

between 37 and 40 weeks of gestation (95%). The reproducibility assessment between two operators is high, showing that the proposed technique is easy to perform by expert sonographers and we have also shown the different US appearance of the uterus along gestation.

Postmortem studies performed in aborted fetuses reported about the shape that the uterus may have in different periods of pregnancy [2]. We have shown in our study that the CUC has a slow growth pattern between 20 and 26 weeks; it is a small structure that could be occasionally difficult to visualize on prenatal ultrasound. However, after 26 weeks, the growth becomes more rapid, probably due to the positive influence of fetal or placental estrogen and progesterone [7]. To our knowledge, this development has not yet been described in prenatal reports. We believe this is an important finding because in pathological situations with coexisting renal or external genitalia defects, the assessment of the uterus might need to be delayed to the late second or third trimester to ensure adequate visualization. So far, there is a large number of cases, about 40% of them in which we were not able to establish undoubtedly the presence of the CUC at 20–24 weeks of gestation. Examination of CUC in the routine 20 weeks is feasible but more complicated and should be done by the specialist and using the best technology available (including TV scan) understanding that it might not be possible in all cases. Our study agrees with a previous publication by Jouannic et al. who described that the visualization of the uterus in 38 fetuses was better in third trimester being 80%–85% of cases at 30–32 weeks, compared to 50% in the second trimester at 20–22 weeks [8].

The identification of internal organs is not only relevant in normal fetuses (as an anatomic check list of normality), but it is also critically important in fetuses with suspect DSD and renal abnormalities. In certain cases, the identification of the uterus and vagina is the clue for the correct diagnosis in the cases with DSD and to orientate genetic or hormonal tests that can be performed prenatally. However, definitive DSD diagnosis could only be achieved after birth in some cases, requiring a multidisciplinary postnatal approach. This is particularly important in fetuses with discrepancy between genetics and ultrasound in the sex assignment. This situation is increasing in routine practice due to the extended use of fetal free DNA in maternal blood in the first trimester [9]. Internal organs are the clue in some cases of DSD and since ovaries are not seen in prenatal US (when normal), the vagina and uterus or CUC are relevant [10, 11]. Moreover, all the protocols for assessment of newborns with suspect DSD include pelvic and abdominal ultrasound in the first days of life [12].

One study published more than ten years ago, reported a reference range for the width and the circumference of the fetal uterus, but did not explain clearly the views to obtain such measurements [3]. Moreover, the mentioned study did not focus on the modification of the shape and US characteristics of the fetal uterus. Our study demonstrates that at about 20 weeks the uterus is small and generates only mild protrusion on the posterior bladder wall and when it is identified, it is usually seen as a hypoechoic round structure. However, in the third trimester of pregnancy it is seen as a solid, round mass pushing the bladder from behind and it is clearly different from the surrounding pelvic structures. We believe that some of the previous publications have not distinguished the different portions of the uterus and it is likely that in some of the small fetuses (included in those reports), the uterus could have been mistaken with the vagina.

## Conclusions

We have added the sagittal view of the pelvic internal organs in the female fetus to improve also the visualization of CUC. We believe that the sagittal plane is important because it allows the visualization not only of the fetal uterus with both cervix (larger) and fundus, but also allows the identification of the vagina and other pelvic structures that are beyond the scope of this work. In our experience it has been very useful in a few cases in which Mullerian malformations in association with renal abnormalities were detected prenatally. The main drawback of this view is that it is not always possible to obtain, and it is likely that longer training is needed to become confident. This approach should be used in the specialized examination when other fetal defects such as renal defects, external genitalia abnormalities or DSD are suspected.

The training to improve the assessment of the internal female organs could be difficult, but we encourage all sonographers to begin looking behind the fetal bladder in male and female fetuses, firstly in the third trimester, to learn how to recognize the difference between them. By doing so, they will be able to identify at least the fetal cervix and uterus, when they become confident, they could move to the 20 weeks anomaly scan.

## Authors contributions

Conceptualization, PA, MB, JSJ, EGM, CC, GA, IAU, JGS, FJFC. Data curation, PA, MB, JSJ, EGM, CC, GA, IAU, JGS, FJFC. Formal analysis, PA, MB, JSJ, EGM, CC, GA, IAU, JGS, FJFC. Investigation, PA, MB, JSJ, EGM, CC, GA, IAU, JGS, FJFC. Methodology, PA, MB, JSJ, EGM, CC, GA, IAU, JGS, FJFC. Project administration, PA,

MB, GA, FJFC. Resources, PA, MB, JSJ, EGM, CC, GA, IAU, JGS, FJFC. Software, PA, MB, JSJ, EGM, CC, GA, IAU, JGS, FJFC. Supervision, PA, MB, JSJ, EGM, CC, GA, IAU, JGS, FJFC. Validation, PA, MB, JSJ, EGM, CC, GA, IAU, JGS, FJFC. Visualization, PA, MB, JSJ, EGM, CC, GA, IAU, JGS, FJFC. Writing—original draft preparation, PA, MB, JSJ, EGM, CC, GA, IAU, JGS, FJFC. Writing—review and editing, PA, MB, JSJ, EGM, CC, GA, IAU, JGS, FJFC. All authors have read and agreed to the published version of the manuscript.

## Ethics statement

This investigation was approved by the Malaga Provincial Research Ethics Committee, belonging to the government of the region of Andalusia, Spain (code 0102-N-24).

## Disclosure statement

The authors of this research have no conflict of interest.

## Funding

The author(s) reported there is no funding associated with the work featured in this article.

## ORCID

Pedro Azumendi  <http://orcid.org/0000-0003-2154-8756>

Marisa Borenstein  <http://orcid.org/0000-0001-9669-0525>


Jesús Salvador Jiménez  <http://orcid.org/0000-0002-7286-8656>

org/0000-0002-7286-8656


Carlos Corrales  <http://orcid.org/0000-0002-0956-6604>

Ignacio Alonso-Usabiaga  <http://orcid.org/0000-0002-5816-2403>

org/0000-0002-5816-2403

Juan Gómez-Salgado  <http://orcid.org/0000-0001-9053-7730>

org/0000-0001-9053-7730

Francisco Javier Fernández-Carrasco  <http://orcid.org/0000-0003-3270-8882>

org/0000-0003-3270-8882

## Data availability statement

Data available under reasonable request to the corresponding author.

## References

- [1] Sadler TW. Urogenital system. Sadler TW. Langman: embriología Médica. 14th ed. Barcelona Wolters Kluwer; 2019; pp. 256–283.
- [2] Sulak O, Cosar F, Malas MA, et al. Anatomical development of the fetal uterus. *Early Hum Dev.* 2007;83(6):395–401. doi: [10.1016/j.earlhumdev.2006.08.007](https://doi.org/10.1016/j.earlhumdev.2006.08.007).
- [3] Soriano D, Lipitz S, Seidman DX, et al. Development of the fetal uterus between 19 and 38 weeks of gestation: in-utero ultrasonographic measurements. *Hum Reprod.* 1999;14(1):215–218. doi: [10.1093/humrep/14.1.215](https://doi.org/10.1093/humrep/14.1.215).
- [4] Pinhas-Hamiel O, Zalel Y, Smith E, et al. Prenatal diagnosis of sex differentiation disorders: the role of fetal ultrasound. *J Clin Endocrinol Metab.* 2002;87(10):4547–4553. doi: [10.1210/jc.2001-011034](https://doi.org/10.1210/jc.2001-011034).
- [5] Glanc P, Umranikar S, Koff D, et al. Fetal sex assignment by sonographic evaluation of the pelvic organs in the second and third trimesters of pregnancy. *J Ultrasound Med.* 2007;26(5):563–569. doi: [10.7863/jum.2007.26.5.563](https://doi.org/10.7863/jum.2007.26.5.563).
- [6] Aydin E, Holt R, Chaplin D, et al. Fetal anogenital distance using ultrasound. *Prenat Diagn.* 2019;39(7):527–535. doi: [10.1002/pd.5459](https://doi.org/10.1002/pd.5459).
- [7] Pryse-Davies J, Dewhurst CJ. The development of the ovary and uterus in the foetus, newborn and infant: a morphological and enzyme histochemical study. *J Pathol.* 1971;103(1):5–25. doi: [10.1002/path.1711030103](https://doi.org/10.1002/path.1711030103).
- [8] Jouannic JM, Rosenblatt J, Demaria F, et al. Contribution of three-dimensional volume contrast imaging to the sonographic assessment of the fetal uterus. *Ultrasound Obstet Gynecol.* 2005;26(5):567–570. doi: [10.1002/uog.1956](https://doi.org/10.1002/uog.1956).
- [9] Gil MM, Accurti B, Santacruz B, et al. Analysis of cell-free DNA in maternal blood in screening for aneuploidies: updated meta-analysis. *Ultrasound Obstet Gynecol.* 2017;50(3):302–314. doi: [10.1002/uog.17484](https://doi.org/10.1002/uog.17484).
- [10] Chitayat D, Glanc P. Diagnostic approach in prenatally detected genital abnormalities. *Ultrasound Obstet Gynecol.* 2010;35(6):637–646. doi: [10.1002/uog.7679](https://doi.org/10.1002/uog.7679).
- [11] Katorza E, Pinhas-Hamiel O, Mazkereth R, et al. Sex differentiation disorders (SDD) prenatal sonographic diagnosis, genetic and hormonal work-up. *Pediatr Endocrinol Rev.* 2009;7(1):12–21.
- [12] Guerrero-Fernández J, Azcona San Julián C, Barreiro Conde J, et al. Guía de actuación en las anomalías de la diferenciación sexual (ADS)/desarrollo sexual diferente (DSD). *An Pediatr.* 2018;89(5):315.e1–315.e19. doi: [10.1016/j.anpedi.2018.06.009](https://doi.org/10.1016/j.anpedi.2018.06.009).