

Accepted Manuscript

Title: *Fasciola hepatica* Induces Eosinophil Apoptosis in the Migratory and Biliary Stages of Infection in Sheep

Author: A. Escamilla M.J. Bautista R. Zafra I.L. Pacheco M.T. Ruiz S. Martínez-Cruz A. Méndez A. Martínez-Moreno V. Molina-Hernández J. Pérez



PII: S0304-4017(15)30098-4
DOI: <http://dx.doi.org/doi:10.1016/j.vetpar.2015.12.013>
Reference: VETPAR 7852

To appear in: *Veterinary Parasitology*

Received date: 14-9-2015
Revised date: 2-12-2015
Accepted date: 14-12-2015

Please cite this article as: Escamilla, A., Bautista, M.J., Zafra, R., Pacheco, I.L., Ruiz, M.T., Martínez-Cruz, S., Méndez, A., Martínez-Moreno, A., Molina-Hernández, V., Pérez, J., *Fasciola hepatica* Induces Eosinophil Apoptosis in the Migratory and Biliary Stages of Infection in Sheep. *Veterinary Parasitology* <http://dx.doi.org/10.1016/j.vetpar.2015.12.013>

This is a PDF file of an unedited manuscript that has been accepted for publication. As a service to our customers we are providing this early version of the manuscript. The manuscript will undergo copyediting, typesetting, and review of the resulting proof before it is published in its final form. Please note that during the production process errors may be discovered which could affect the content, and all legal disclaimers that apply to the journal pertain.

***Fasciola hepatica* Induces Eosinophil Apoptosis in the Migratory and Biliary Stages of Infection in Sheep**

A. Escamilla^a, M.J. Bautista^a, R. Zafra^a, I.L. Pacheco^a, Ruiz^a, M.T., S. Martínez-Cruz^b, A.Méndez^a, A. Martínez-Moreno^b, V. Molina-Hernández^c, J.Pérez^a,

^aDepartment of Anatomy and Comparative Pathology, Faculty of Veterinary Medicine, University of Córdoba, Spain

^bDepartment of Animal Health (Parasitology), Faculty of Veterinary Medicine, University of Córdoba, Spain.

^cSchool of Biological Sciences, Queen's University Belfast, Belfast, UK.

Corresponding author:

José Pérez,

Dep. Anatomía y Anatomía Patológica Comparadas

Edificio de Sanidad Animal, Campus de Rabanales, Ctra. Madrid-Cádiz km 396

14014 Córdoba, Spain

Tel: +34 957218178, Fax: +34 957218682

e-mail: anlpearj@uco.es

Research Highlights:

- Eosinophil apoptosis was common in acute hepatic lesions during the migratory stage.
- Eosinophil apoptosis was also found in the periphery of enlarged bile ducts containing flukes.
- Eosinophil apoptosis may play a role for *F. hepatica* survival during infection.

Abstract

The aim of the present work was to evaluate the number of apoptotic eosinophils in the livers of sheep experimentally infected with *Fasciola hepatica* during the migratory and biliary stages of infection. Four groups (n = 5) of sheep were used; groups 1-3 were orally infected with 200 metacercariae (mc) and sacrificed at 8 and 28 days post-infection (dpi), and 17 weeks post-infection (wpi), respectively. Group 4 was used as an uninfected control. Apoptosis was detected using immunohistochemistry with a polyclonal antibody against anti-active caspase-3, and transmission electron microscopy (TEM). Eosinophils were identified using the Hansel stain in serial sections for caspase-3, and by ultrastructural features using TEM. At 8 and 28 dpi, numerous caspase-3⁺ eosinophils were mainly found at the periphery of acute hepatic necrotic foci. The percentage of caspase -3⁺ apoptotic eosinophils in the periphery of necrotic foci was high (46.1 to 53.9) at 8 and 28 dpi, respectively, and decreased in granulomas found at 28 dpi (6%). Transmission electron microscopy confirmed the presence of apoptotic eosinophils in hepatic lesions at 8 and 28 dpi. At 17 wpi, apoptotic eosinophils were detected in the infiltrate surrounding some enlarged bile ducts containing adult flukes. This is the first report of apoptosis induced by *F. hepatica* in sheep and the first study reporting apoptosis in eosinophils in hepatic inflammatory infiltrates *in vivo*. The high number of apoptotic eosinophils in acute necrotic tracts during the migratory and biliary stages of infection suggests that eosinophil apoptosis may play a role in *F. hepatica* survival during different stages of infection.

Key words: apoptosis; caspase-3; eosinophil; *Fasciola hepatica*; sheep.

1. Introduction

Fasciola hepatica causes liver fluke disease in temperate climates and is responsible for major economic losses in animal production (Spithill et al., 1999). This disease is also considered a serious public health problem in humans (McManus and Dalton, 2006). *F. hepatica* often causes chronic infection, which implies the development of strategies by the parasite to modulate/suppress the host immune response (Dalton et al., 2013; Morphew et al., 2013). The parasite modulation of the host immune response is a serious obstacle to obtaining protective vaccines against *F. hepatica* in ruminants (Toet et al., 2014; Molina-Hernández et al., 2015).

In helminth infections, eosinophils play important roles either in developing tissue pathology (Cadman et al., 2014) and in the host effector response by releasing cytotoxic granule proteins and various lipid mediators (Klion and Nutman, 2004; Cadman et al., 2014). An effective response in rats infected with *F. hepatica* has been associated with a significant increase in eosinophil infiltration of the gut lamina propria in early post-infection stages (Van Milligen et al., 1998, 1999). In *F. hepatica* infected rats, peritoneal eosinophils producing very high levels of nitric oxide (NO) have been reported (Jedlina et al., 2011). In sheep, peritoneal eosinophils and macrophages, as well as mammary gland eosinophils from *F. gigantica* resistant Indonesian thin-tail (ITT) sheep were able to kill juvenile *F. gigantica* in vitro by antibody-dependent cytotoxicity, but they did not kill larvae of *F. hepatica*, suggesting that eosinophils are important effector cells involved in the resistance of sheep to *F. gigantica* (Piedrafita et al., 2007). Previous studies have reported that bovine eosinophils incubated with bovine serum were unable to damage juvenile *F. hepatica*, but major basic protein (MBP) obtained from bovine eosinophils was able to kill juvenile *F. hepatica* at very low concentration (Duffus et al., 1980).

Apoptosis of effector cells such as eosinophils has been reported as a mechanism of immunosuppression during helminth infections (Shin et al., 2000; Yan et al., 2008; Zepeda et al., 2010). It has been reported that *F. hepatica* induces eosinophil apoptosis in the hepatic inflammatory infiltrate in rats *in vivo* (Serradell et al., 2007). *In vitro* studies in the rat model have demonstrated that secreted excretory products of *F. hepatica* (FhESP) are able to induce apoptosis in eosinophils and peritoneal macrophages, suggesting that apoptosis in effector cells may play a role in the host immune evasion/suppression induced by *F. hepatica* infection (Serradell et al., 2007; Guasconi et al., 2012). Although the mechanisms of immune modulation/suppression induced by *F. hepatica* are a serious obstacle to developing protective vaccines in ruminants (Molina-Hernández et al., 2015), to date, apoptosis has not been investigated in ruminants infected with *F. hepatica*.

Several markers of apoptosis in tissue sections have been investigated, among them activated caspase-3 immunohistochemistry is considered an easy, sensitive, and reliable method for detecting and quantifying apoptosis in histological sections (Duan et al., 2003, Resendes et al., 2004). Transmission electron microscopy is also a useful technique to detect apoptotic cells and to identify eosinophils based on the morphological features of their cytoplasmic granules (Duffin et al., 2009) and it allow to evaluate ultrastructure of apoptotic eosinophils (Balic et al., 2006).

The aim of the present work was to evaluate the presence and number of eosinophils undergoing apoptosis in hepatic inflammatory infiltrates from sheep experimentally infected with *F. hepatica* during the migratory (8 and 28 days post-infection -dpi) and biliary stages of infection (17 weeks post-infection -wpi). Activated caspase-3 immunohistochemistry was used for quantifying eosinophil apoptosis and transmission electron microscopy was used to evaluate ultrastructure of apoptotic eosinophils.

2. Materials and methods

2.1. Experimental design

Twenty 7-month-old female Merino-breed sheep were used for this study. All animals were obtained from a liver fluke-free farm. Animals were purchased at 1 month of age and housed indoors in the experimental farm of the University of Córdoba until they reached the appropriate age for challenge. All animals were tested monthly for parasite eggs by fecal sedimentation; the results were negative. In addition, all animals were tested for serum IgG specific for *F. hepatica* cathepsin L1 by ELISA prior to challenge and all of them were negative. The sheep were allocated into four groups of five animals each: groups 1, 2 and 3 were orally infected with one dose of 200 metacercariae (Ridgeway Research Ltd. Gloucestershire, UK); group 4 was used as the uninfected negative control. Animals were sacrificed by intravenous injection of thiobarbital at different stages of infection. Groups 1 and 2 were sacrificed at 8 and 28 days post-infection (dpi) and the animals of group 3 were sacrificed at 17 weeks post-infection (wpi). The experiment was approved by the Bioethics Committee of the University of Cordoba (No. 1118) and was performed taking into account European (2010/63/UE) and Spanish (RD 1201/2005) directives on animal experimentation.

2.2. Histopathology and fluke burdens

At necropsy, the duodenum was ligated proximally and distally to the ductus choledochus (8 to 10 cm) and the liver was photographed on the visceral and diaphragmatic aspects for gross evaluation. Liver tissue samples showing hepatic lesions were collected and fixed in 10% neutral buffered formalin for 24 h, then routinely processed and embedded in paraffin wax. Four micron-thick tissue sections were stained with hematoxylin and eosin (H&E) for histopathology. Fluke burden was conducted in animals from group 3 as follows: gallbladders were opened and flukes were recovered, then the bile ducts were carefully opened and flukes

were removed with blunt forceps. Finally, the livers were cut into small pieces (1 cm³) and washed in hot water to collect the remaining flukes.

Hansel's stain was used in liver tissue sections to identify the presence of eosinophils. Two 4 µm-thick tissue serial sections were obtained. All these tissue sections were deparaffinized and dehydrated through a graded ethanol series. The first section was stained with Hansel's stain, the second by immunohistochemistry for active caspase-3. For Hansel's stain, tissue sections were incubated for 1 min with eosin, washed in distilled water and incubated for 1 min in methylene blue, then washed in distilled water, dehydrated and mounted.

2.3. Immunohistochemistry (IHC)

Formalin-fixed, paraffin-embedded sections and the avidin-biotin-peroxidase method (Zafra et al., 2013b) were used for the IHC study. A polyclonal (pAb) rabbit anti-human caspase-3 antibody (RP096, Diagnostic BioSystems, Pleasanton, USA) was used as a marker for apoptosis. The primary antibody reacts with cleaved activated caspase-3 but does not recognize full-length caspase-3 or other cleaved caspases; according to the manufacturer, this antibody cross-reacts with activated ovine caspase-3. Liver tissue sections from 8 dpi in which apoptosis had been detected by transmission electron microscopy were used as positive controls.

2.4. Transmission electron microscopy (TEM)

For the ultrastructural study, fresh liver samples from groups 1, 2 and 4 were used. In groups 1 and 2, samples were collected from whitish tortuous tracts, cut into 1-mm cubes, fixed in 2.5% glutaraldehyde, post-fixed in 1% osmium tetroxide and embedded in Epon 812. Thin sections (50 nm) were stained with uranyl acetate and lead citrate and examined and photographed using a Jeol Jem 1400 transmission electron microscope.

2.5. Gross lesions evaluation and cell counting

Gross pictures of livers were used to evaluate gross damage (hemorrhages and necrotic tracts at 8 and 28 dpi, and fibrosis and scars at 17 wpi) as reported Zafra et al (2008) using the Image Pro 6.0 software (Media Cybernetics, Silver Spring, USA). The perimeter of the diaphragmatic and visceral aspects of the liver was delineated and the total area obtained, then, the perimeter of the damaged areas was delineated and the area obtained. The percentage of damaged area was then expressed as mean value \pm SD per group.

Cell counting was carried out in 10 fields of 0.08 mm² per animal randomly selected at the periphery of necrotic foci (8 dpi), necrotic foci and granulomas (28 dpi) and inflammatory infiltrate surrounding large bile ducts with erosive cholangitis (17 wpi). Cell counting was carried out in tissue sections stained with Hansel's technique (eosinophils), and IHC (caspase-3⁺ eosinophils and apoptotic bodies). Results are given as mean \pm SD per group.

2.6. Statistical analyses

The Kolmogorov-Smirnov test was applied to decide whether distributions were parametric. Comparison between pairs of groups was made with the Mann-Whitney U test. $p < 0.05$ was considered significant.

3. Results

3.1. Gross pathology and fluke burdens

All control livers from group 4 showed no gross changes on either the diaphragmatic or visceral surface. Livers from group 1 showed numerous white spots with reddish spots and occasional whitish tortuous tracts ranging from 0.3 to 1 cm in length located on the liver surface, mainly on the diaphragmatic aspect of the left lobe. Livers from group 2 showed numerous whitish tortuous tracts ranging from 0.5 to 3 cm in length, whitish-grey patches

ranging up to 1x1x2.5 cm and occasional reddish spots, mainly involving the left lobe. Livers from group 3 showed enlarged, whitish gall bladders and bile ducts, which contained brown fluid and numerous adult flukes. Numerous tortuous greyish scars were found on the liver surface, mainly involving the left lobe. The percentage of damaged hepatic surface was 3.5 ± 1.2 at 8 dpi, 8.7 ± 2.3 at 28 dpi and 23.4 ± 6.7 at 17 wpi. The number of flukes in the four animals from group 4 was 54, 40, 34 and 58 (mean 46.5 ± 1.36).

3.2. Histopathological study

Livers from group 4 showed no histopathological changes. Portal spaces showed occasional lymphocytes, but eosinophils were not found in negative control livers. All animals from group 1 presented necrotic foci and focal hemorrhages mainly involving subcapsular areas. Necrotic foci showed abundant cell debris and mild to moderate infiltrates of eosinophils, often with pyknotic nuclei. Necrotic tracts started 0.5-1.5 mm behind migrating larvae.

Livers from group 2 presented similar acute necrotic foci and tracts with eosinophil infiltration. In addition, the majority of necrotic foci were surrounded by a core of large activate macrophages and an outer layer of lymphocytes, plasma cells and eosinophils, conforming to the definition of a granuloma.

Histopathological changes in the livers from group 3 were typical of chronic fasciolosis Adult flukes were present within severely enlarged bile ducts often showing epithelial erosion, portal fibrosis and a variable amount of inflammatory infiltration, mainly composed of eosinophils, lymphocytes and plasma cells.

3.3. Apoptosis detected by caspase-3 expression

Livers from negative control sheep (group 3) did not show caspase-3⁺ inflammatory cells. At 8 dpi, numerous inflammatory cells located at the periphery of necrotic foci, as well as cell

debris (apoptotic bodies), expressed caspase-3, whereas the inflammatory infiltrate not associated with necrotic areas showed only occasional caspase-3⁺ inflammatory cells. The pattern of immunostaining was both cytoplasmic and nuclear. Serial sections stained with Hansel's technique allowed us to identify eosinophils (Figs. 1 and 2). The percentage of caspase-3⁺ eosinophils with respect to caspase-3⁻ eosinophils at the periphery of necrotic foci was 46.1% and 53.9% at 8 and 28 dpi, respectively (Table 1), whereas at the periphery of granulomas, the percentage of caspase-3⁺ eosinophils was only 6% (Table 1). At 17 wpi, eosinophils located the inflammatory infiltrate surrounding some hyperplastic bile ducts, often containing adult flukes, showed numerous caspase-3⁺ cells (Fig. 3), whereas the inflammatory infiltrate not associated with enlarged bile ducts only showed occasional caspase-3⁺ cells.

3.4. Apoptosis detected by transmission electron microscopy

The TEM study confirmed apoptosis in eosinophils in livers from groups 1 and 2. The ultrastructural features of eosinophils consist of a bilobed nucleus and typical cytoplasmic oval granules ranging from 0.5 to 1 μm in diameter with moderately electron dense matrix material and a highly electron-dense crystalloid core (Fig. 4). Apoptotic TEM changes consisted of margination-condensation of chromatin (early changes) and cytoplasmic and nuclear fragmentation while maintaining cell membranes and organelles (Fig. 4).

4. Discussion

Hansel's stain has been used to identifying and quantifying eosinophils in tissues (Nguyen et al., 2012). In the liver tissue sections examined in the present study, eosinophils were identified more easily using Hansel's stain than H&E staining. We used Hansel's stain as a

counterstain for caspase-3 immunohistochemistry, but the dark brown color of the immunostaining masked the bright red cytoplasmic granules of eosinophils and did not allow for the identification of this cell type, this is why we used serial sections.

Caspase-3 is an effector caspase that plays a crucial role during apoptosis, since it directly activates enzymes that are responsible for DNA fragmentation. Activated or cleaved caspase-3 has been used as a marker of apoptosis via immunohistochemistry in healthy tissues and in helminth-infected tissue sections (Resendes et al., 2004, Chen et al., 2008, Mkupasi et al., 2013). The absence of apoptotic inflammatory cells in non-infected control livers in the present study contrasts with the presence of apoptosis in healthy pig lymphoid tissues, and may be due to the small number of inflammatory cells present in the healthy sheep liver compared with those in lymphoid organs (Resendes et al., 2004).

In the present study, apoptotic eosinophils were also identified by TEM in liver samples at 8 and 28 dpi. Ultrastructurally, eosinophils were identified by the typical cytoplasmic granules with an electron dense core according to the features reported in human (Duffin et al., 2009) and ovine (Balic et al., 2006) eosinophils. The condensation and fragmentation of the nucleus with an intact cytoplasmic membrane was found in apoptotic eosinophils in this work and has also been reported in TEM studies of human (Duffin et al., 2009) and ovine (Balic et al., 2006) eosinophils. Apoptotic eosinophils attached to *Haemonchus contortus* in the gastric tip of sheep were degranulated (Balic et al., 2006); by contrast, in the present study, apoptotic eosinophils found in the liver during the migratory stage of *F. hepatica* contained typical granules. This finding suggests that during the migratory stage of *F. hepatica*, degranulation of eosinophils is not the cause of apoptosis.

During the migratory stage (8 and 28 dpi), acute necrotic foci and tracts were found behind migrating larvae, suggesting they induced hepatic necrotic tracts, in agreement with previous

reports in sheep (Meeusen et al., 1995, Zafra et al., 2013a,b). The majority of apoptotic eosinophils were found in the periphery of these acute necrotic foci and tracts, while they were occasional in portal infiltrates and granulomas and inflammatory infiltrates not associated with necrotic foci or tracts. Moreover, in the chronic stage of infection (17 wpi), the majority of apoptotic eosinophils were found in the vicinity of large bile ducts, often containing adult flukes inside, and occasionally in inflammatory infiltrates associated with granulomas, fibrotic chronic tracts or portal spaces with smaller bile ducts. This distribution of apoptotic eosinophils suggests that products released by migrating or adult *F. hepatica* may induce the local recruitment of eosinophils. It is possible that products released by *F. hepatica* induces eosinophil apoptosis, which is supported by *in vitro* studies reporting that the excretory products (ESP) of *F. hepatica* are able to induce apoptosis in rat eosinophils and macrophages (Serradell et al., 2007, Serradell et al., 2009, Guasconi et al., 2012) and ESP from the trematode *Paragonimus westermani* are able to induce eosinophil apoptosis (Min et al., 2004). Alternatively, enzymes released by eosinophils may cause lytic necrosis and apoptosis, which is supported by the crucial role of eosinophil in mediating tissue damage and granuloma formation in *Schistosoma mansoni* (Silveira-Lemos et al., 2008). Further studies immunolocalizing ESP antigens from *F. hepatica* in hepatic tissue sections from infected sheep are required to confirm if *F. hepatica* ESP are able to induce apoptosis in sheep inflammatory cells.

Apoptosis of effector cells of the innate response such as eosinophils has been reported as a mechanism of local immunosuppression during helminth infections such as *P. westermani* (Shin et al., 2000, Min et al., 2004) and the cestode *Taenia solium* (Yan et al., 2008) and *Taenia crassica* (Zepeda et al., 2010). In fasciolosis, eosinophils appear to play a crucial role in the effector host response; thus, an effective response in rats infected with *F. hepatica* has been associated with a significant increase in eosinophil infiltration of the gut lamina propria

during early post-infection stages (Van Milligen et al., 1998, 1999). In *F. gigantica* resistant Indonesian thin-tail (ITT) sheep, peritoneal eosinophils and macrophages are able to kill juvenile *F. gigantica in vitro* by an antibody-dependent cytotoxicity mechanism dependent on NO production, but they do not kill the larvae of *F. hepatica*, suggesting that eosinophils are important effector cells involved in the resistance of sheep to *F. gigantica* (Piedrafita et al., 2007). The results of the present work revealed a high number of apoptotic eosinophils in acute necrotic foci at 8 and 28 dpi, while the number of apoptotic eosinophils decreased significantly in necrotic granulomas at 28 dpi. Since acute necrotic foci occur behind migrating larvae, and eosinophils are crucial effector of the effective host innate response, apoptosis of this effector cell may be an important mechanism used by *F. hepatica* larvae to evade the host innate response during the hepatic migratory stage in which the parasites are more exposed to the host immune response than when they reach the biliary system.

In summary, the present work is the first report of eosinophil apoptosis during the migratory and biliary stages of *F. hepatica* infection in sheep. Eosinophil apoptosis was detected by active caspase-3 tissue expression and transmission electron microscopy, and it was found in a high number of eosinophils mainly located at the periphery of acute necrotic tracts during the migratory stage of infection, suggesting that this may be a mechanism by which the parasite evades the host response. Further studies are required to investigate the presence of apoptosis in other inflammatory cells such as macrophages and lymphocytes as well as the presence of apoptosis in peritoneal inflammatory cells.

Acknowledgments

This work was supported by EU grants (FPVII-265862-PARAVAC, H2020-635408-PARAGONE) and the Spanish Ministry of Science grant AGL2009-08726. TEM studies were carried out by the Central Services for Research of the University of Córdoba (SCAI).

References

Balic, A., Cunningham, C.P., Meeusen, E.N., 2006. Eosinophil interactions with *Haemonchus contortus* larvae in the ovine gastrointestinal tract. *Parasite Immunol.* 28, 107-115.

Cadman, E.T., Thyse, K.A., Bearder, S., Cheung, A.Y., Johnston, A.C., Lee, J.J., Lawrence, R.A., 2014. Eosinophils are important for protection, immunoregulation and pathology during infection with nematode microfilariae. *PLoS Pathog.* 10(3):e1003988. doi: 10.1371/journal.ppat.1003988.

Chen, K.M., Lee, H.H., Lai, S.C., Hsu, L.S., Wang, C.J., Liu, J.Y. , 2008. Apoptosis in meningoencephalitis of *Angiostrongylus cantonensis*-infected mice. *Exp. Parasitol.* 119, 385-390.

Dalton, J.P., Robinson, M.W., Mulcahy, G., O'Neill, S.M., Donnelly, S., 2013. Immunomodulatory molecules of fasciola hepatica: Candidates for both vaccine and immunotherapeutic development. *Vet. Parasitol.* 195, 272-285.

Duan, W.R., Garner, D.S., Williams, S.D., Funckes-Shippy, C.L., Spath, I.S., Blomme, E.A. 2003. Comparison of immunohistochemistry for activated caspase-3 and cleaved cytokeratin 18 with the TUNEL method for quantification of apoptosis in histological sections of PC-3 subcutaneous xenografts. *J. Pathol.* 199, 221-228.

Duffin, R., Leitch, A.E., Sheldrake, T.A., Hallett, J.M., Meyer, C., Fox, S., Alessandri, A.L., Martin, M.C., Brady, H.J., Teixeira, M.M., Dransfield, I., Haslett, C., Rossi, A.G., 2009. The

CDK inhibitor, R-roscovitine, promotes eosinophil apoptosis by down-regulation of Mcl-1. FEBS Letters 583, 2540-2546.

Guasconi, L., Serradell, M.C., Masih, D.T., 2012. *Fasciola hepatica* products induce apoptosis of peritoneal macrophages. Vet. Immunol. Immunopathol. 148, 359-363.

Jedlina, L., Kozak-Lunggren, M., Wedrychowicz, H. 2011. In vivo studies of the early, peritoneal, cellular and free radical response in rats infected with *Fasciola hepatica* by flow cytometric analysis. Exp. Parasitol. 128, 291-297.

Klion, A.D. and Nutman, T.B., 2004. The role of eosinophils in host defense against helminth parasites. J. Allergy Clin. Immunol. 113, 30-37.

McManus, D.P. and Dalton, J.P., 2006. Vaccines against the zoonotic trematodes *Schistosoma japonicum*, *Fasciola hepatica* and *Fasciola gigantica*. Parasitol. 133, Suppl: S43-61.

Meeusen, E., Lee, C.S., Rickard, M.D., Brandon, M.R., 1995. Cellular responses during liver fluke infection in sheep and its evasion by the parasite. Parasite Immunol. 17, 37-45.

Min, D.Y., Lee, Y.A., Ryu, J.S., Ahn, M.H., Chung, Y.B., Sim, S., Shin, M.H., 2004. Caspase-3-mediated apoptosis of human eosinophils by the tissue-invading helminth *Paragonimus westermani*. Int. Arch. Allergy Immunol. 133, 357-364.

Mkupasi, E.M., Sikasunge, C.S., Ngowi, H.A., Leifsson, P.S., Johansen, M.V., 2013. Detection of cysteine protease in *Taenia solium*-induced brain granulomas in naturally infected pigs. *Vet. Parasitol.* 197, 360-363.

Molina-Hernández, V., Mulcahy, G., Pérez, J., Martínez-Moreno, A., Donnelly, S., O'Neill, S.M., Dalton, J.P., Cwiklinski, K., 2015. *Fasciola hepatica* vaccine: We may not be there yet but we're on the right road. *Vet. Parasitol.* 208, 101-111.

Morphew, R.M., Hamilton, C.M., Wright, H.A., Dowling, D.J., O'Neill, S.M., Brophy, P.M., 2013. Identification of the major proteins of an immune modulating fraction from adult *Fasciola hepatica* released by nonidet p40. *Vet. Parasitol.* 191, 379-385.

Nguyen, K.H., Suzuki, H., Wakasugi, T., Hohchi, N., Hashida, K., Kitamura, T., Shibata, M., 2012. Expression of epidermal growth factors, erbBs, in the nasal mucosa of patients with chronic hypertrophic rhinitis. *ORL J. Otorhinolaryngol. Relat. Spec.* 74, 57-63.

Piedrafita, D., Estuningsih, E., Pleasance, J., Prowse, R., Raadsma, H.W., Meeusen, E.N., Spithill, T.W., 2007. Peritoneal lavage cells of Indonesian thin-tail sheep mediate antibody-dependent superoxide radical cytotoxicity in vitro against newly excysted juvenile *Fasciola gigantica* but not juvenile *Fasciola hepatica*. *Infect. Immun.* 75, 1954-1963.

Resendes, A.R., Majo, N., Segales, J., Espadamala, J., Mateu, E., Chianini, F., Nofrarias M., Domingo, M., 2004. Apoptosis in normal lymphoid organs from healthy normal, conventional pigs at different ages detected by tunel and cleaved caspase-3

immunohistochemistry in paraffin-embedded tissues. *Vet. Immunol. Immunopathol.* 99, 203-213.

Serradell, M.C., Guasconi, L., Cervi, L., Chiapello, L.S., Masih, D.T., 2007. Excretory-secretory products from *Fasciola hepatica* induce eosinophil apoptosis by a caspase-dependent mechanism. *Vet. Immunol. Immunopathol.* 117, 197-208.

Serradell, M.C., Guasconi, L., Masih, D.T., 2009. Involvement of a mitochondrial pathway and key role of hydrogen peroxide during eosinophil apoptosis induced by excretory-secretory products from *Fasciola hepatica*. *Mol. Biochem. Parasitol.* 163, 95-106.

Shin, M.H., 2000. Excretory-secretory product of newly excysted metacercariae of *Paragonimus westermani* directly induces eosinophil apoptosis. *Korean J. Parasitol.* 31, 17-23.

Silveira-Lemos, D., Teixeira-Carvalho, A., Martins-Filho, O.A., Alves Oliveira, L.F., Costa-Silva, M.F., Matoso, L.F., de Souza, .LJ., Gazzinelli, A., Corrêa-Oliveira, R. 2008. Eosinophil activation status, cytokines and liver fibrosis in *Schistosoma mansoni* infected patients. *Acta Trop.* 108:150-159.

Spithill, T.W., Smooker, P.M., Sexton, J.L., Bozas, E., Morrison, C.A., Creaney, J., Parsons, J.C., 1999. Development of vaccines against *Fasciola hepatica*. In: Dalton, J.P. (Ed.), *Fasciolosis*, CAB International, Wallingford, UK, pp. 377–401.

Toet, H., Piedrafita, D.M., Spithill, T.W. 2014. Liver fluke vaccines in ruminants: strategies, progress and future opportunities. *Int. J. Parasitol.* 44, 915-27.

Van Milligen, F.J., Cornelissen, J.B., Hendriks, I.M., Gaasenbeek, C.P., Bokhout, B.A., 1998. Protection of *Fasciola hepatica* in the gut mucosa of immune rats is associated with infiltrates of eosinophils, IgG1 and IgG2a antibodies around the parasites. *Parasite Immunol.* 20, 285-292.

Van Milligen, F.J., Cornelissen, J.B., Bokhout, B.A., 1999. Protection against *Fasciola hepatica* in the intestine is highly correlated with eosinophil and immunoglobulin G1 responses against newly excysted juveniles. *Parasite Immunol.* 21, 243-251.

Yan, H.L., Xue, G., Mei, Q., Ding, F.X., Wang, Y.Z., Sun, S.H., 2008. Calcium-dependent proapoptotic effect of *Taenia solium* metacestodes annexin b1 on human eosinophils: A novel strategy to prevent host immune response. *Int. J. Biochem. Cell. Biol.* 40, 2151-2163.

Zafra, R., Buffoni, L., Martinez-Moreno, A., Perez-Ecija, A., Martinez-Moreno, F. J., Perez, J., 2008. A study of the liver of goats immunized with a synthetic peptide of the Sm14 antigen and challenged with *Fasciola hepatica*. *J. Comp. Pathol.* 139, 169-176.

Zafra, R., Perez-Ecija, R.A., Buffoni, L., Moreno, P., Bautista, M.J., Martinez-Moreno, A., Mulcahy, G., Dalton, J.P., Perez, J., 2013a. Early and late peritoneal and hepatic changes in goats immunized with recombinant cathepsin L1 and infected with *Fasciola hepatica*. *J. Comp. Pathol.* 148, 373-384.

Zafra, R., Perez-Ecija, R.A., Buffoni, L., Pacheco, I.L., Martinez-Moreno, A., LaCourse, E.J., Perally, S., Brophy, P.M., Perez, J., 2013b. Early hepatic and peritoneal changes and immune response in goats vaccinated with a recombinant glutathione transferase sigma class and challenged with *Fasciola hepatica*. Res. Vet. Sci. 94, 602-609.

Zepeda, N., Solano, S., Copitin, N., Fernandez, A.M., Hernandez, L., Tato, P., Molinari, J.L., 2010. Decrease of peritoneal inflammatory CD4(+), CD8(+), CD19(+) lymphocytes and apoptosis of eosinophils in a murine *Taenia crassiceps* infection. Parasitol. Res. 107, 1129-1135.

Figure Legends

Figure 1. Liver, 8 days post-infection. Caspase-3. Necrotic focus (N) showing cell debris and numerous inflammatory cells, many of them expressing caspase-3 (brown, arrow). Note a bile duct (B) with severe inflammatory infiltrate in the portal space negative for caspase-3 except for one cell (brown). ABC method, x400.

Figure 2. Liver, 8 days post-infection. Serial section of same area observed in Figure 6. Note the bile duct (B) surrounded by a severe inflammatory infiltrate and a necrotic focus (N) with abundant cellular debris and moderate inflammatory infiltrate, the majority of cells with a red cytoplasm are eosinophils. Hansel staining, x400.

Figure 3. Liver, 17 weeks post-infection. Detail of a bile duct showing the lumen (L) with a lack of epithelium (erosive cholangitis) and numerous caspase-3⁺ cells in the associated inflammatory infiltrate. ABC method, x400.

Figure 4. Liver, 8 days post-infection. Eosinophils showing normal ultrastructural features (E) and apoptotic eosinophils (AE) showing condensed, electron dense nuclei and typical granules with electron dense structures. An apoptotic neutrophil (AN) with a multilobed electron dense nucleus and typical round to oval electron dense cytoplasmic granules is also observed. Transmission electron microscopy. Bar = 2 μ m.

Figure 1

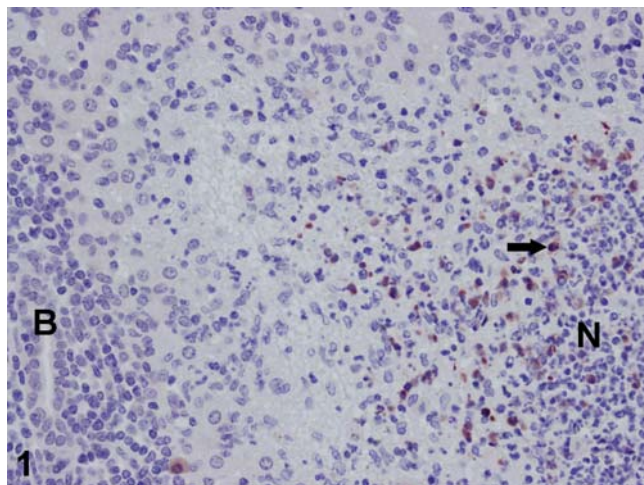


Figure 2

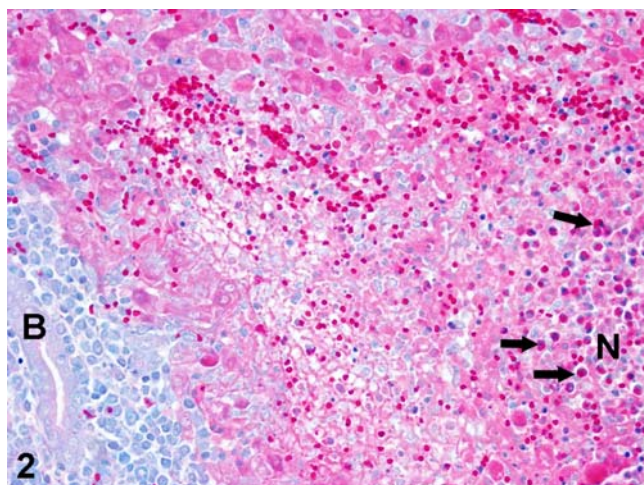


Figure 3

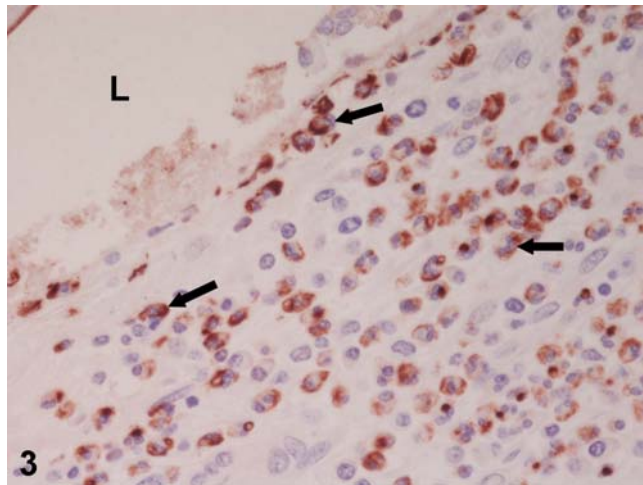


Figure 4

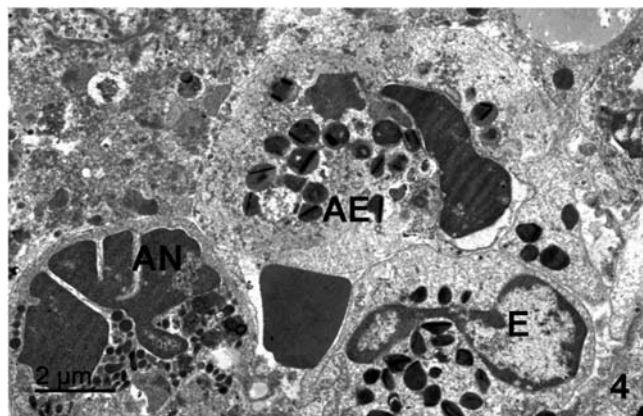


Table 1. Number of caspase-3⁺ eosinophils and apoptotic bodies in *F. hepatica* infected sheep at 8 days post-infection (dpi), 28 dpi and 17 weeks post-infection (wpi) and in negative control sheep. Results are expressed as mean±SD per field of 0.08 mm².

	8 dpi	28 dpi		17 wpi	controls
	NF	NF	Granulomas		
caspase-3 ⁺ eosinophils	10.6±1.8	13.7±5.7	1.3±1,0	17.3±7.8	0
caspase-3 ⁻ eosinophils	12.4±1.9	11.7±3.7	20.3± 8.2	29.3±12.8	0
% caspase-3 ⁺ eosinophils	46.1	53.9	6.0	37.1	0
caspase-3 ⁺ A.B.	18.5±0.9	32.6*±2.2	6.7‡±3.5	11.3±5.7	0

NF: necrotic foci; AB: apoptotic bodies.

*Significant differences (P<0.05) respect to 8 dpi.

‡ Significant differences (P<0.05) respect to NF at 8 and 28 dpi.